

Implantation of an epicardial lead through mini-thoracotomy as an alternative for patients with lead-related endocarditis who require permanent pacing



Karol Bartczak¹, Andrzej Walczak¹, Sławomir Jander¹, Radosław Zwoliński¹, Andrzej Banyś², Arkadiusz Ammer¹, Jerzy Krzysztof Wrancisz³, Ryszard Jaszewski¹

¹Department of Cardiac Surgery, Medical University of Lodz

²Department of Anesthesiology and Cardiac Intensive Care, Medical University of Lodz

³Department of Electrophysiology, Chair of Cardiology and Cardiac Surgery, Medical University of Lodz

Kardiologia i Torakochirurgia Polska 2013; 10 (1): 62–66

Abstract

We present a case of a 60-year-old man who underwent mitral valve replacement, coronary artery bypass grafting and numerous electrophysiological procedures which resulted in infective endocarditis and the necessity of extracting his permanent pacemaker (PPM). In spite of multiple targeted antibiotic therapies and sustained fever, the patient had a second PPM implanted through mini-thoracotomy to provide permanent pacing.

Key words: infection of heart pacing systems, epicardial pacing, mini-thoracotomy.

Introduction

The progress in electrocardiology has caused the number of permanent pacemaker (PPM) implantations to increase. Together with the number of these procedures, the incidence of infections has grown significantly as well, in the majority of cases leading to infective endocarditis (IE). Infective endocarditis is diagnosed in about 10-25% of patients with PPM infection [1]. In such cases, prognoses are very unfavorable. Targeted antibiotic therapy alone can improve it only slightly. The extraction of the PPM is a radical, but adequate form of managing this type of complication. However, in patients who are completely dependent on continuous heart pacing, it is very problematic. Therefore, we present a case of a 60-year-old man who ultimately required the implantation of an epicardial lead through mini-thoracotomy.

Case report

The sixty-year-old man with ischemic cardiomyopathy [NYHA functional class III, left ventricular ejection fraction (LVEF) 18%] underwent mitral valve replacement and coro-

Streszczenie

Przedstawiamy przypadek 60-letniego chorego po implantacji sztucznej zastawki mitralnej i rewaskularyzacji serca, po licznych procedurach elektrofizjologicznych, które spowodowały infekcyjne zapalenie wsierdza wymagające eksplantacji wszczepionych układów. Pomimo wielokrotnej celowanej antybiotykoterapii, występowania stanów gorączkowych, w celu zapewnienia stymulacji choremu drogą minitorakotomii implantowano nasierdziowy układ stymulacji.

Słowa kluczowe: zakażenie układów stymulujących serce, nasierdziowa stymulacja, minitorakotomia.

nary artery bypass grafting (venous graft to the right coronary artery) in 2002. He had a history of numerous electrophysiological procedures, including a recent dual-chamber (DDD) PPM upgrade (implanted in January, 2011) with cardiac resynchronization therapy defibrillator

(CRT-D) (QRS 130 ms). In May 2011, he was admitted to the hospital due to pacemaker pocket decubitus with skin perforation and purulent infection. On 15 September 2011, the infected PPM was removed after the implantation of a temporary pacemaker lead to the right ventricle via the right internal jugular vein, which was connected to an external pacemaker attached to the patient's neck (Fig. 1). The three infected leads were uneventfully and completely removed by direct traction, after which the patient was referred for targeted antibiotic therapy. On October 27th, an attempt to implant an implantable cardioverter-defibrillator (ICD) through a left side approach was made. It was, however, unsuccessful due to the occlusion of the left subclavian vein. Despite the lack of other systemic infection signs, the patient continued to experience periodic fever. The patient fulfilled the modified Duke criteria. After a car-

Address for correspondence: Karol Bartczak, Department of Cardiac Surgery, Medical University of Lodz, Sterlinga 1/3, 91-425 Łódź, tel. +48 42 212 18 31, e-mail: bartczakkarol@op.pl

diac surgical consultation, the patient was qualified for transthoracic implantation of an epicardial screw-in lead. At that time, the patient was in NYHA functional class III/IV with ejection fraction of 18%. On November 24th, under general anesthesia, a small incision of 5-7 cm was made, which partly included a previous sternotomy scar. Through this approach the pericardial sack was opened, the apex of the heart was exposed and a Medtronic 5071-35 cm lead was implanted epicardially (Fig. 2 and 3). A Biotronic Cyclos 990SR pacemaker was put into the small pocket under the left rectus abdominis muscle (Fig. 4 and 5). The parameters were the same as those observed after standard implantations. The procedure was ended by the removal of

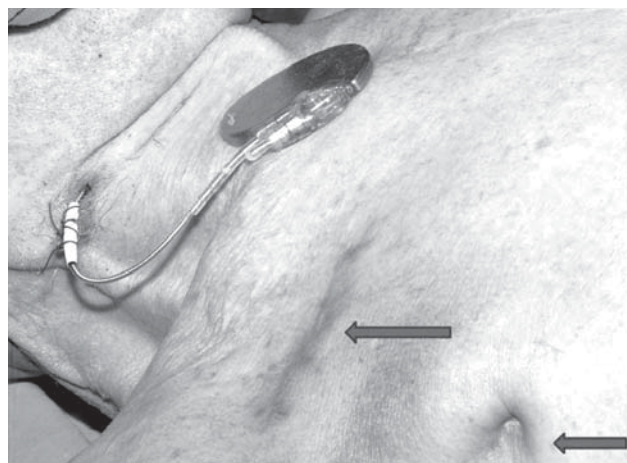


Fig. 1. Temporary pacing with external pacemaker attached to the patient's neck. Numerous scars after previous pacing systems are visible

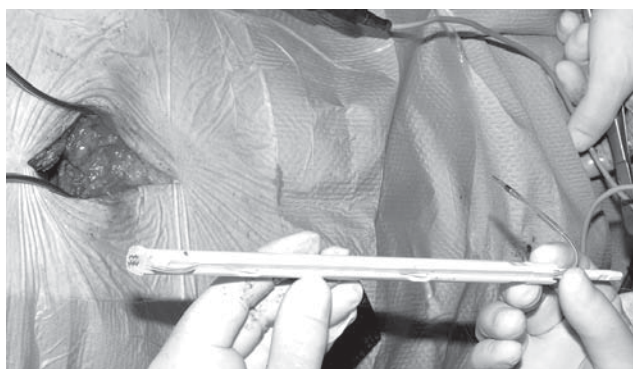


Fig. 2. The implantation kit of the epicardial screw-in lead before the procedure

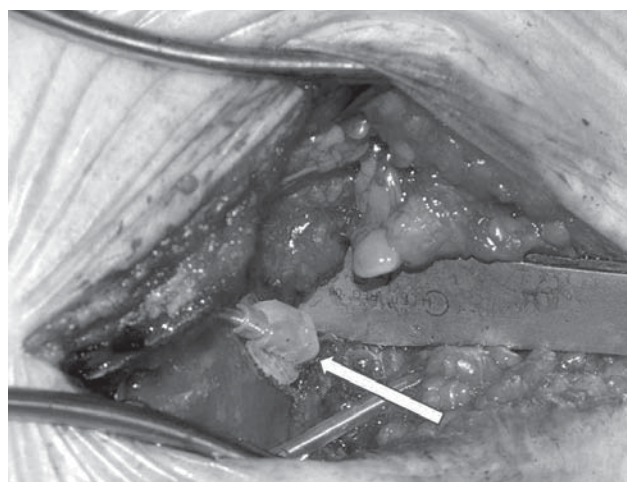


Fig. 3. The lead is implanted into the apex of the heart

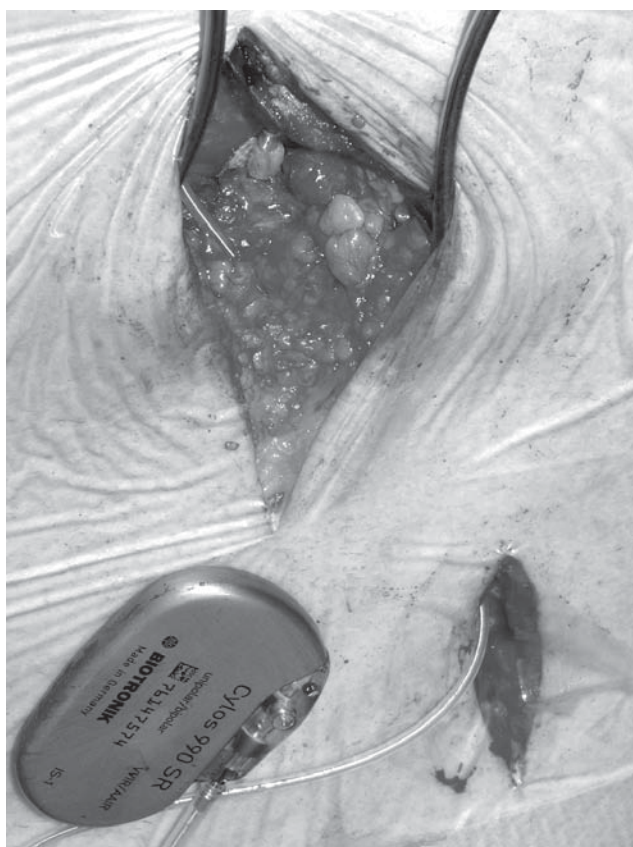


Fig. 4. The epicardial pacemaker is ready to close

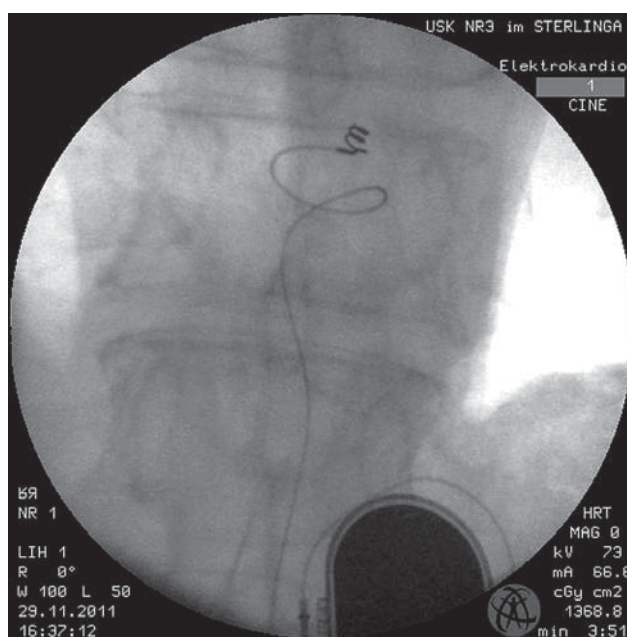


Fig. 5. The X-ray image of the implanted system

the temporary lead and the external pacemaker. Holter ECG confirmed proper ventricular inhibited (VVI) pacing without any complex ventricular arrhythmias. The surgical treatment of the patient was treated as temporary until the acquisition of negative blood culture tests. The patient was discharged from the hospital in good clinical condition.

Discussion

The presented case exemplifies the dynamic development of electro-cardiology. However, more frequent interventions in the existing systems (e.g. substituting a PPM with an ICD) may potentially lead to infections in the new system. Such a case was presented above as an example of a very complex and difficult management.

Infective endocarditis caused by a previously implanted PPM is a significant clinical problem, especially in patients who are completely dependent on heart pacing. The implantation of a new lead into the infected environment may cause its infection even if the patient previously underwent a long-term targeted antibiotic therapy. How long should we wait after the removal of an infected system before we can safely implant a new one?

The lack of unequivocal guidelines in this field reflects the huge individualization of this issue. According to some authors [2] a period from 36-72 hours to 2 weeks is long enough if there are no vegetations on the cardiac valves. Otherwise, a 6-week period of antibiotic therapy is recommended as in the case of typical IE [3-5]. Managing patients who require continuous stimulation between the removal of the old infected system and the implantation of a new permanent one constitutes a separate clinical issue. When inserting a temporary endocavitary pacemaker lead connected to an external pacemaker, attached to the patient's skin as a bridge to the ultimate implantation of the new system [6, 7], it is not possible to guarantee that another foreign body placed in a potentially infected environment will not cause IE. This method, proposed by Bellot, is relatively safe; however, the risk of infection caused by the soft endocavitary screw-in pacemaker lead is high. This particular complication occurred in the present case. This is why we chose a method which is a little more invasive, but nevertheless reliable – transthoracic implantation of the epicardial screw-in lead and placing the pacemaker device under the left rectus abdominal muscle. This completely excluded the risk of infection by any intracardiac foreign body. According to guidelines, a negative blood culture test should be obtained 72 hours prior to implantation, but in this particular case the patient was pacemaker dependent. In the author's opinion, leaving the infected lead inside the heart or implanting a new lead into the infected environment would not solve the problem. Implanting a new lead endocardially into the infected environment may very likely cause an extension of the infection onto the new implanted lead and does not guarantee a successful treatment. This is why the authors decided to implant a new lead epicardially despite the present bacteremia and remove the infected system from the inside of the heart to increase the chances of suc-

cessful IE treatment and decrease the risk of infection of the new lead in the pacemaker-dependent patient.

That method is especially recommended for patients who previously underwent median sternotomy (for any reason), who require PPM and for whom typical pacemaker implantation is not possible.

Sako *et al.* [8] presented a case of DDD epicardial pacemaker implantation in the pectoral region through mini-sternotomy in a patient with superior vena cava occlusion. Systems implanted using this method are much less susceptible to infection than those implanted using traditional means. Even in case of an infection (which practically does not occur) the removal of such systems is easier and safer than the removal of endocavitary systems. The implantation of PPM with this method requires a little more surgical experience, but an electro-cardiac surgeon should be fully capable of performing it. On the other hand, the implantation of CRT through this approach in those patients who previously underwent cardiac surgery would be far more difficult and dangerous due to the necessity of preparing a much bigger surface of the heart (CRT has three leads). The danger of lesion or bleeding of the heart would also become more significant. Due to the above, the authors decided to implant a VVI PPM (one lead) in this particular patient to minimize the risk related to the surgery, bearing in mind that this solution was just a temporary bridge to the final implantation of an ICD via the standard approach (the authors are planning an upgrade to the ICD in further follow-up). Today, the so-called hybrid procedures are becoming more and more common. They combine percutaneous extraction of the infected system and reimplantation of the new system through small mini-thoracotomy using video-assisted techniques. Therefore, they are even less invasive than the method described in this article. Mair *et al.* [9] presented a group of 80 patients in whom they implanted bipolar epicardial systems through left sided mini-thoracotomy using video-assisted techniques.

According to the opponents of epicardial pacing, it is less physiological, more energy consuming, and more frequently leads to exit block and undersensing, even if steroid electrodes are used [10].

Our results do not confirm the above remarks. We have followed up 16 patients in whom we had decided to implant epicardial leads for different reasons during a period of 5 years. Our observations are very encouraging and will be published soon. It must, however, be emphasized that this method of PPM implantation may be chosen only in select cases, after a full, deep and comprehensive analysis of every single patient.

In conclusion, the implantation of an epicardial screw-in pacemaker lead is a method of choice in numerous cases, as it provides effective and durable heart pacing.

References

1. Sohail MR, Uslan DZ, Khan AH, Friedman PA, Hayes DL, Wilson WR, Steckelberg JM, Jenkins SM, Baddour LM. Infective endocarditis complicating permanent pacemaker and implantable cardioverter-defibrillator infection. *Mayo Clinic. Proc* 2008; 83: 46-53.

2. Mazurek M, Grzegorzewski A, Kutarski A. Infekcja łoży stymulatora z następowym zapaleniem wsierdza u chorego po reimplantacji stymulatora serca leczona usunięciem układu stymulującego serca i kardiowerterów-defibrylatorów. *Kardiologia Pol* 2009; 67: 305-309.
3. Baddour LM, Epstein AE, Erickson CC, Knight BP, Levison ME, Lockhart PB, Masoudi FA, Okum EJ, Wilson WR, Beerman LB, Bolger AF, Estes NA 3rd, Gewitz M, Newburger JW, Schron EB, Taubert KA; American Heart Association Rheumatic Fever, Endocarditis, and Kawasaki Disease Committee; Council on Cardiovascular Disease in Young; Council on Cardiovascular Surgery and Anesthesia; Council on Cardiovascular Nursing; Council on Clinical Cardiology; Interdisciplinary Council on Quality of Care; American Heart Association. Update on cardiovascular implantable electronic device infections and their management: a scientific statement from the American Heart Association. *Circulation* 2010; 121: 458-477.
4. Michałkiewicz D, Kutarski A. Pacjent po odektrodowym zapaleniu wsierdza – co dalej...? *Folia Cardiologica Excerpta* 2009; 4: 132-135.
5. Wożakowska-Kapłon B, Wesołowska K, Kutarski A. Odektrodowe zapalenie wsierdza jako późne powikłanie po implantacji stymulatora serca. *Kardiologia Pol* 2011; 69: 265-269.
6. Rastan AJ, Doll N, Walther T, Mohr FW. Pacemaker dependent patients with device infection – a modified approach. *Eur J Cardiothorac Surg* 2005; 27: 1116-1118.
7. Lepillier A, Otmani A, Waintraub X, Ollitrault J, Le Heuzey J, Lavergne T. Temporary transvenous VDD pacing as a bridge to permanent pacemaker implantation in patients with sepsis and haemodynamically significant atrioventricular block. *Europace* 2012; 14: 981-985.
8. Sako H, Hadama T, Shigemitsu O, Miyamoto S, Anai H, Wada T, Iwata E, Hamamoto H. An implantation of DDD epicardial pacemaker through ministernotomy in a patient with a superior vena cava occlusion. *Pacing Clin Electrophysiol* 2003; 26: 778-780.
9. Mair H, Jansens JL, Lattouf OM, Reichart B, Dabritz S. Epicardial lead implantation techniques for biventricular pacing via left lateral mini-thoracotomy, video-assisted thoracoscopy, and robotic approach. *Heart Surg Forum* 2003; 6: 412-417.
10. Esperer HD, Mahmoud FO, von der Emde J. Is epicardial dual chamber pacing a realistic alternative to endocardial DDD pacing? Initial results of a prospective study. *Pacing Clin Electrophysiol* 1992; 15: 155-161.